

**PATIENT**

Steve Zagorski

**SPECIES**

Feline

**BREED**

DSH

**SEX**

Female Spayed

**AGE**

6 years

**WEIGHT**

8.8lbs

**INTERPRETED BY**Maggie Machen Lamy,  
DVM, DACVIM  
(Cardiology)**IMAGING PERFORMED BY**

Kim Liedberg

**HOSPITAL NAME**

SVS Imaging WI

**REFERRING VET**

Dr. Miller

**INVOICE**

29270

**DATE**

2/27/23

**PRESENTING CLINICAL SIGNS**

History: Elevated ProBNP 1465. Assess prior to dental.

**ECHOCARDIOGRAM FINDINGS**

2D, m-mode, color flow and doppler imaging is available. The left ventricular wall is normal in dimension. There is a mildly hyperechoic endocardium consistent with mild fibrosis. The endocardium also appears mildly remodeled. The papillary muscles are normal in size and hyperechoic. The left atrium is normal in size. The right atrium is normal in size. The right ventricle appears normal. The mitral valve is normal in structure and mobility with trace MR. No other obvious valve regurgitation. Blood flow through both the LVOT and RVOT is normal in velocity. No pleural or pericardial effusion seen. No obvious cardiac tumors.

**CARDIAC CHART**

FELINE CARDIAC PARAMETERS	BODY WEIGHT (kg)	HR (BPM)	IVSd (cm) (Moise, Pipers)	LVIDd (cm) (Moise, Pipers)	LWVd (cm) (Moise, Pipers)	FS (%)	EF (%)
NORMAL PARAMETER	-----	150-240	0.35-0.55	<2 (mean 1.5)	3.5-0.55	35-67	80-100
PATIENT	4.0	NM	0.41	1.35	0.38	68	96
FELINE CARDIAC PARAMETERS	LA/AO (Boon)	LA/AO HEART BASE (Swe) (Abbott)	LA 2D short axis Base view (cm) (Abbott)	LVOT VEL (m/s)	RVOT VEL (m/s)	E max (m/s)	
NORMAL	<1.5	<1.3	<1.2	<1.6	<1.3	<0.9	
PATIENT	1.4	1.4	1.34	0.7	0.8	NM	

*\*Note: All measurements based upon multi-modal images and methods. An average value is reported.*  
 Adapted from June Boon, Veterinary Echocardiography, 1998  
 Abbott J & MacLean H JVIM 2006;20: 111-119, Moise et al. Am J Vet Res 47:1476, 1986. Pipers et al. Am J Vet Res 40:882, 1979.

**INTERPRETATION OF THE FINDINGS & FURTHER RECOMMENDATIONS**

Overtly normal cardiac structure and function. The LV wall thickness is normal, and there is no evidence of elevated left atrial pressure or underlying pathology at this time. There is mild remodeling and fibrosis of the left ventricular wall, which is considered likely a normal age-related finding. Given these findings, no medications are indicated.

No obvious structural cause for BNP elevation is seen here. A flaw of the BNP test is false positives, which may be the case; however, alternative causes for elevation should be considered, including decreased renal clearance, hypertension, etc. If no obvious cause is identified, reassessing this patient in 6-12 months is recommended to ensure early disease was not missed.

Anesthetic risk is considered mild. With remodeling and diastolic stiffening, there is an elevated risk for fluid overload in this patient and judicious IV fluid use is recommended. Heart rate stimulating drugs such as atropine, glycopyrrolate or ketamine should be avoided unless medically necessary. Risk for complication with steroid use typically follows LA dilation, which in this case is low. That being said, any cat can experience unexpected signs of intolerance and monitoring of RR/RE is advised particularly in the initiation phase.

**IMAGING PERFORMED BY**

svsmobileimaging.com 309 - 737 - 3070



**Clinical Sonography & Telectology**

EDUCATIONAL TELECONSULTATION SERVICES™

1-800-838-4268 info@sonopath.com SonoPath.com

**PATIENT**

Steve Zagorski

**SPECIES**

Feline

**BREED**

DSH

**SEX**

Female Spayed

**AGE**

6 years

**WEIGHT**

8.8lbs

**INTERPRETED BY**

Maggie Machen Lamy,  
DVM, DACVIM  
(Cardiology)

**IMAGING PERFORMED BY**

Kim Liedberg

**HOSPITAL NAME**

SVS Imaging WI

**REFERRING VET**

Dr. Miller

**INVOICE**

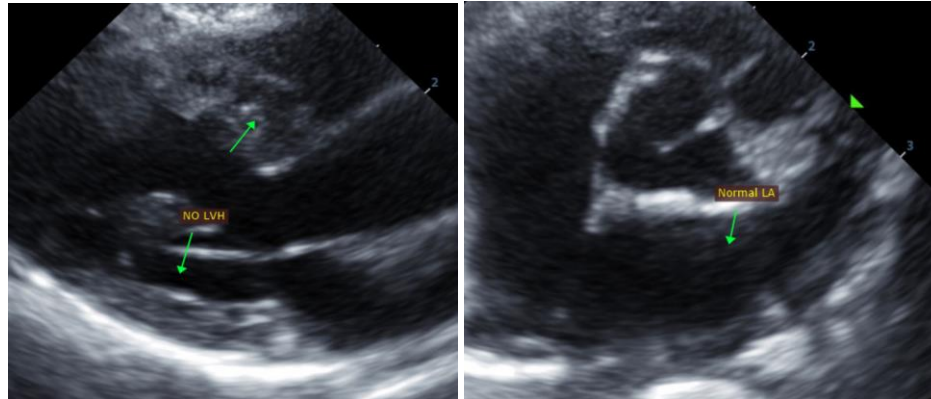
29270

**DATE**

2/27/23

A recheck echocardiogram is recommended in 1 year to screen for any progressive changes.

**IMAGES**



The information and recommendations provided are based on the images presented by the referring veterinarian. No evaluation can be communicated regarding pathology that was not visible in the image/video clips provided.

Thank you for this referral. If the clinical or image interpretation does not parallel your findings or if I can be of any further assistance, please contact me.

**Maggie Machen Lamy, DVM**  
Diplomate of the American College of Veterinary Internal Medicine (Cardiology)  
info@sonopath.com